

Michael Connelly, M.D.  
Karine Ngoie, PA-C  
Interventional Pain Medicine

Riverwalk  
354 Merrimack Street  
Lawrence MA  
(978) 687-2321

One Park Way  
Haverhill MA  
(978) 373-9733



### The NENA Difference

New England Neurological is a unique practice environment for treating patients with spine pain.

- Seamless collaboration with Neurosurgery, as well as Neurology, Psychology, Psychiatry and Physiatry .
- Extensive experience treating hundreds compression fractures, with and without kyphoplasty.
- Consultation for inpatients ensures continuity of care.

### References

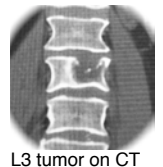1. Saad F, Lipton A, Cook R, Chen YM, Smith M, Coleman R. Pathologic fractures correlate with reduced survival in patients with malignant bone disease. *Cancer*. 2007 Oct 15;110(8):1860-7.
2. Rose PS, Laufer I, Boland PJ, et al. Risk of fracture after single fraction image guided intensity-modulated radiation therapy to spinal metastasis. *J Clin Oncol* 2009; 27:5075-79
3. Lad SP, Patil CG, Lad EM, Boakye M. Trends in pathological vertebral fractures in the United States: 1993 to 2004. *J Neurosurg Spine*. 2007 Sep;7(3):305-10.
4. Berenson J, Pflugmacher R, Jarzem P, Zonder J, Schechtman K, Tillman JT, Ashraf T, Vrionis F. Balloon Kyphoplasty versus Non-surgical Fracture Management for Treatment of Painful Vertebral Compression Fractures in Patients with Cancer: A Multicentre, Randomised Controlled Trial. *Lancet Oncol*. 2011 Mar;12(3):225-235

## Compression Fracture Update

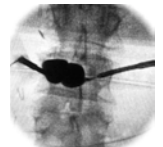
### ★ New Level 1 RCT Data For Cancer Patients

#### Case Example: Metastatic Compression Fracture L3

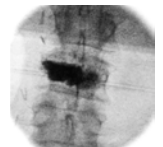
A 50 year old male was referred with pain from an L3 compression fracture due to metastatic renal cell cancer. He presented in January 2008 with CLL and later developed metastatic renal cancer. In March 2010 he underwent ORIF with titanium rod and XRT for femur metastasis. In September he developed back pain from an L3 metastatic fracture, and underwent XRT. He had persistent back pain that radiated to the left leg in the L3 dermatome. In January 2011 CT demonstrated progressive collapse of the left lateral L3 vertebral body and foraminal stenosis compressing the L3 nerve root. Balloon kyphoplasty was completed in February, along with transforaminal steroid injection along the L3 nerve root. The patient had complete relief of both back and leg pain, and discontinued opioid medication.



L3 tumor on CT



Balloon inflation



Cement deposition

This case demonstrates the complimentary role of radiation therapy and kyphoplasty. Radiation treats the tumor and pain. Kyphoplasty stabilizes bone, provides much more immediate pain relief, and may restore vertebral body height and reduce deformity.

#### The Problem of Pathologic Fractures in Cancer Patients

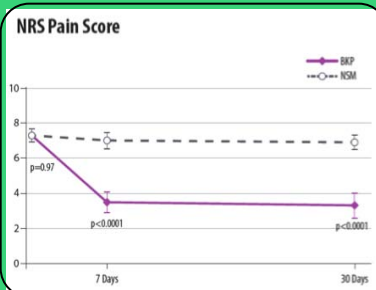
Bone metastasis is common in cancer patients. Pathologic vertebral compression fractures occur most commonly in multiple myeloma (25%), breast (25%) and lung (14%) cancer<sup>1</sup>. Radiation therapy for treatment of metastasis can contribute to osteonecrosis.<sup>2</sup> There were 55,000 inpatient admissions for pathologic vertebral fractures in 2004 with a “national bill” inpatient hospitalization of \$1.4 billion.<sup>3</sup> In addition to pain, pathologic fractures are associated with reduced survival, independent of other variables.<sup>1</sup>

#### March 2011: Results of CAFE (Cancer Patient Fracture Evaluation) Trial Published Kyphoplasty versus Non-surgical Management of Painful Vertebral Fractures

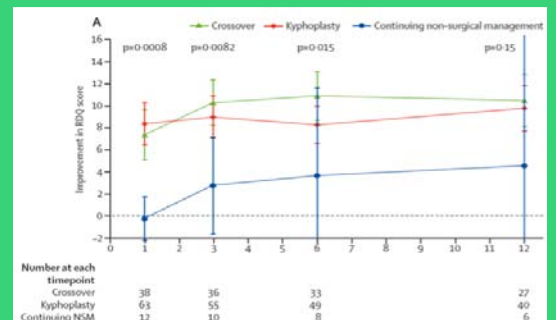
134 patients in 22 sites in the USA, Canada, Europe and Australia with painful compression fractures were randomized to non-surgical treatment or balloon kyphoplasty. The primary endpoint was Roland Morris Disability (RDQ) score and pain score. Compared with non-surgical treatment, patients treated with balloon kyphoplasty experienced:

- ★ Immediate reduction in pain, with difference sustained at 12 months
- ★ Improvement in quality of life score, sustained at 12 months
- ★ Reduction in disability scores, sustained at 12 months.
- ★ Less use of pain medication

The majority of patients in the non-surgical treatment group requested crossover to the kyphoplasty group after one month (38/64). Other findings include significant height restoration for thoracic fractures treated with kyphoplasty. There was no difference in the incidence of new fractures between kyphoplasty and non-surgical treatment groups.



Less Pain immediately



Less Disability out to 12 months